

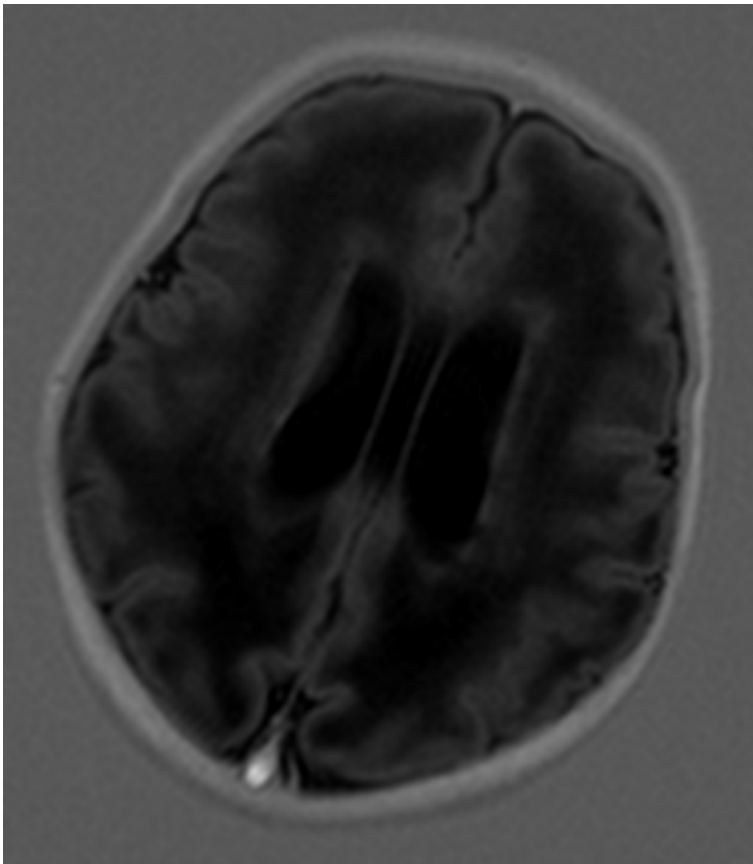
## **COLPOCEPHALY IN AN INFANT WITH CONGENITAL CMV**

*Author: Dr Althaf Ansary, University of Glasgow, Glasgow*

*Dr Harcharan Singh, Speciality Doctor, Paediatrics, Royal Alexandra Hospital, Paisley*

*Dr Graham Stewart, Consultant Neonatologist, Royal Alexandra Hospital, Paisley*

Colpocephaly is a rare abnormality of the brain, described as persistence of primitive foetal configuration of lateral ventricles. It is a disorder of multiple and diverse aetiologies. Herein we report a case of colpocephaly with periventricular calcification and abnormal simple cortical folding following congenital CMV infection in the first trimester.



**Fig:** Axial section of Brain MRI showing parallel orientation of the bodies of the lateral ventricle. Early periventricular calcification, abnormal simple cortical folding and hypointense cerebral white matter is evident.

**Disclosure:** This case report has been accepted as a poster for a regional UK conference, REASON 2015.